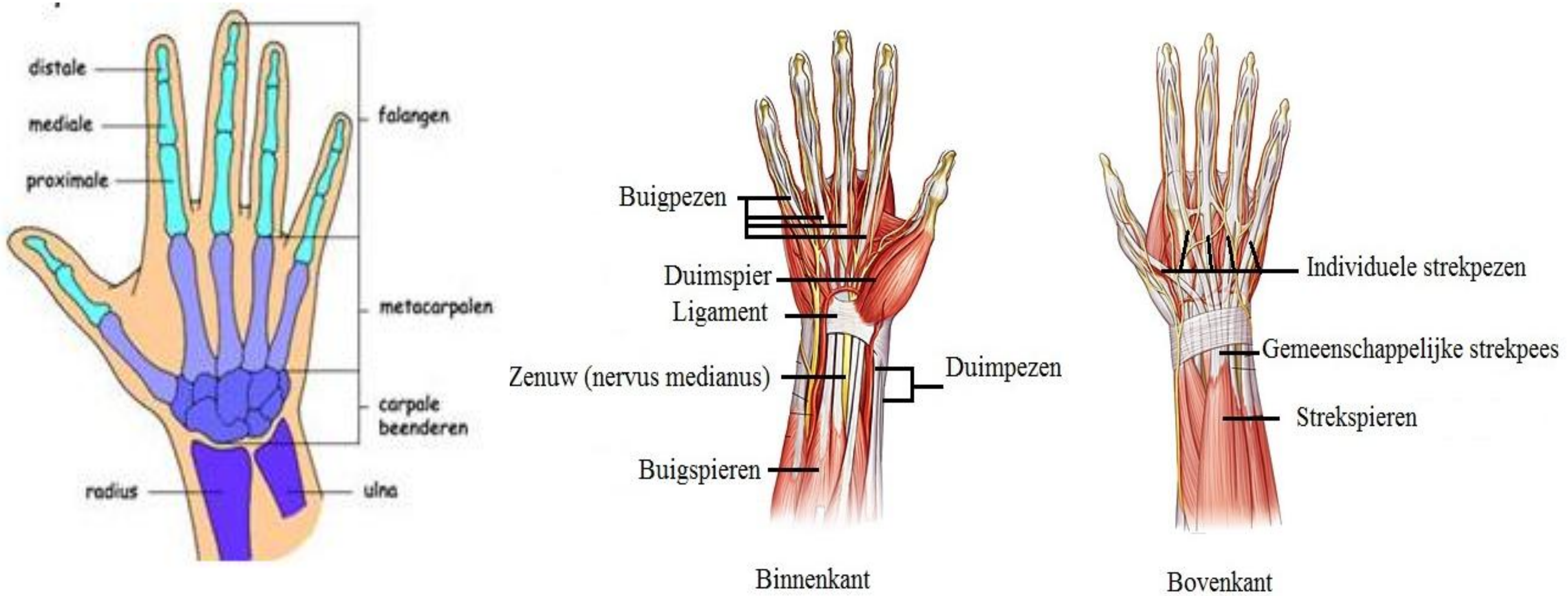
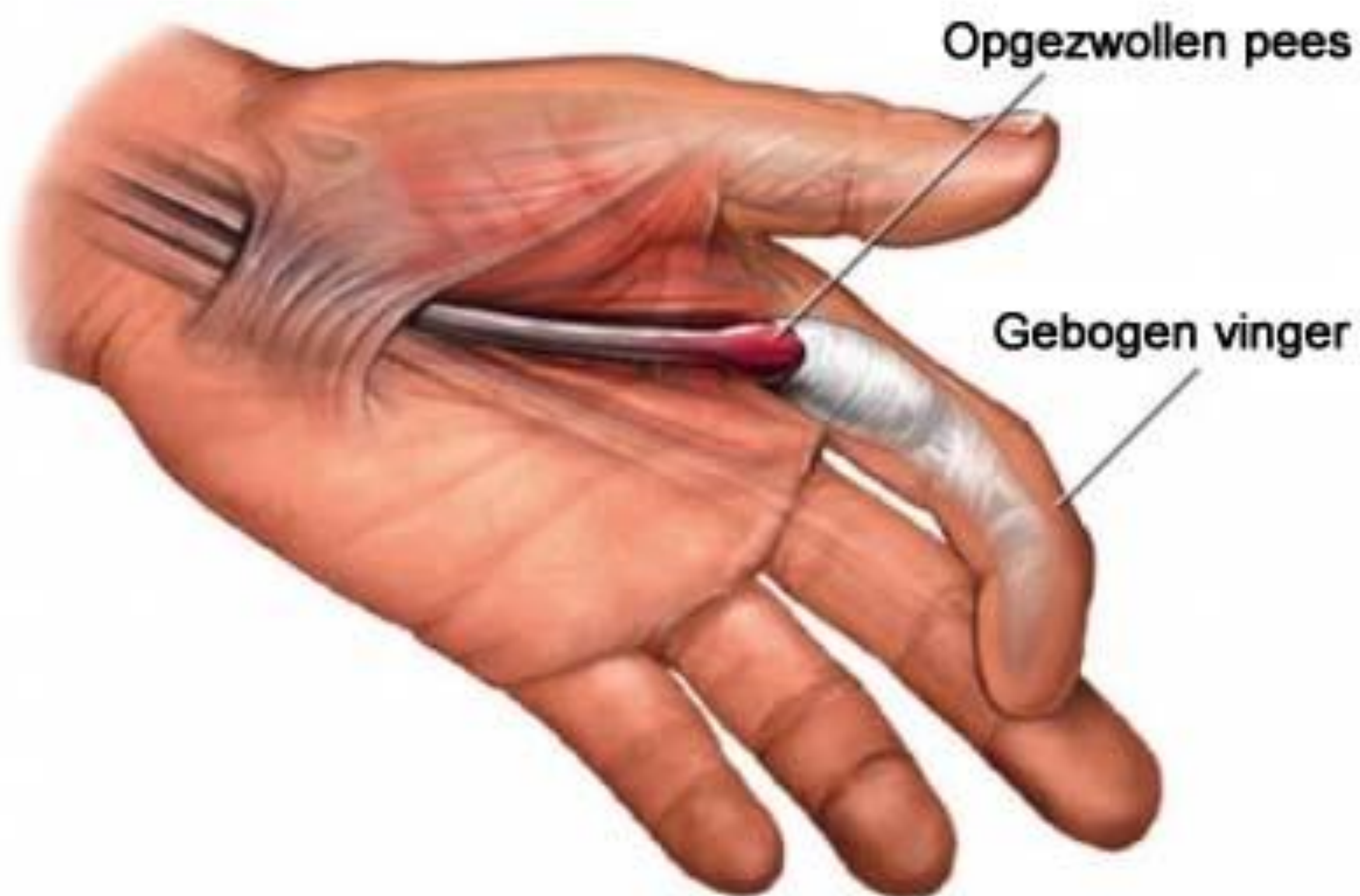


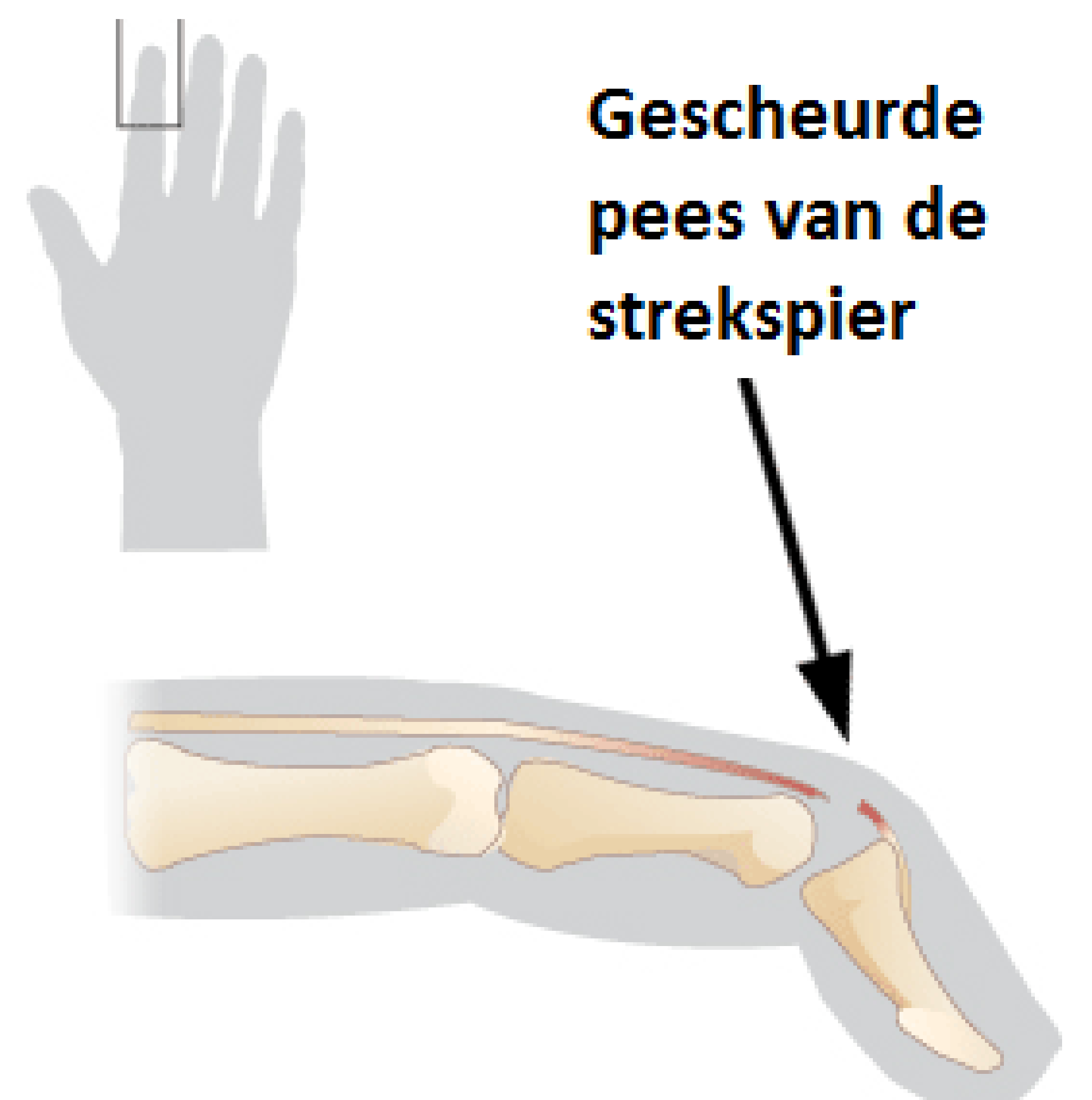# 8. Aandoeningen van de hand en pols



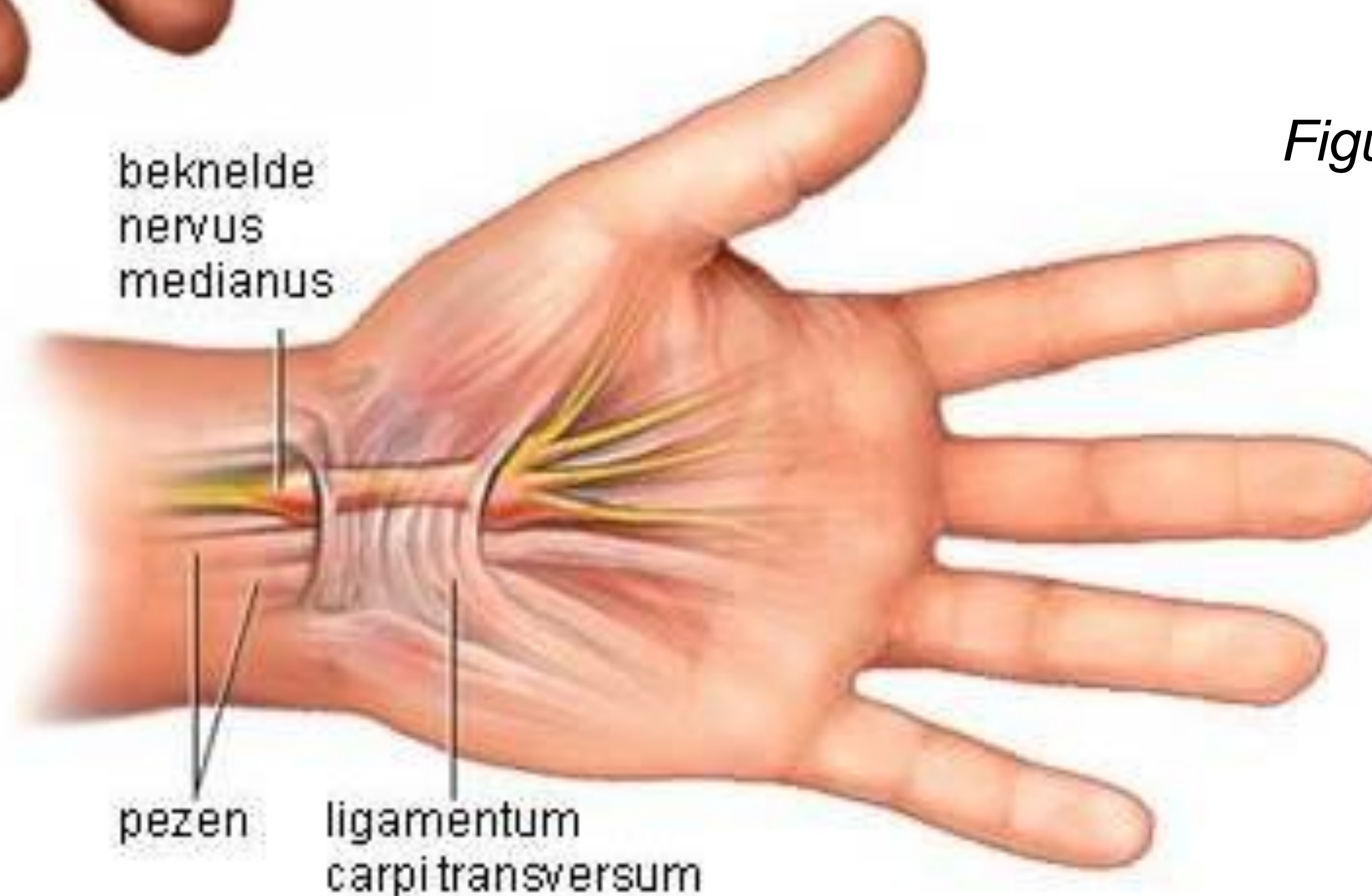
Figuur 1: Anatomie van de hand



Figuur 2: Triggerfinger



Figuur 3: Malletvinger



Figuur 4: Carpale Tunnel Syndroom